

# Common Physical Abnormalities of Captive Birds

Birds often arrive in sheltering facilities with physical or behavioral conditions that require remedy but are not necessarily signs that a bird is diseased or ill or has a life-threatening condition. Most are the result of poor care, inadequate diet, previous injury or trauma, and lack of proper grooming. The most common are dull or matted plumage, bald spots, missing toes or toenails, and overgrown beaks and nails. Birds are prey species, and their instinct is to hide illness. Examination by a qualified avian veterinarian to determine the underlying cause and to ascertain if the signs are an early indication of a more serious illness is always recommended.

## WHAT TO LOOK FOR

In general, the bird should be alert, vocal, active, responsive to stimuli, and interested in the surrounding environment. They should be able to perch steadily, preen themselves, and exhibit a healthy appetite. If there are no other overt signs of illness (i.e. bleeding, lesions, discharge from the eyes or nostrils, respiratory distress, swelling, dragging a wing or leg, lethargy, or fluffed and lying prone on the cage floor), chances are the bird is otherwise in good health.

## FEATHER ABNORMALITIES: PLUCKING VS. MUTILATING

The origins of feather destruction behaviors are complex; they can be medical, psychological, environmental or a combination thereof. Some birds simply over preen or shred their feathers, others pluck out some or all of the feathers within their reach, while others graduate to the most serious self-mutilating of their skin and underlying tissue. For shelters, the most serious concern is a bird with an open wound that is the result of feather plucking or self-mutilating. These birds should receive immediate medical attention.

Feather plucking and shredding, dull or matted plumage, ragged wing or tail feathers, dark stress bars, and generally poor feather quality are often caused by factors such as:

- Nutritional deficiencies: insufficient food, diets lacking in essential nutrients
- Psychological factors: boredom, lack of exercise and mental stimulation, stress, separation anxiety, or lack of socialization with humans and/or other birds
- Excessive confinement in too small a cage
- Allergies; bacterial, viral infection or protozoal infection (Giardia)
- Low humidity or infrequent bathing, airborne toxins
- Developmental factors: chicks deprived of physical contact with parents, too early or forced weaning, juvenile did not fledge, insufficient social interaction with parents, siblings & flock
- Breeding; hormonal imbalance

Some conditions can be mitigated through improved diet or medical intervention. Boredom or lack of physical or mental stimulation is often a cause. Providing the bird with an increased variety of enrichment activities may help to reduce feather plucking. Repeated feather plucking over a long period often results in permanent damage to the feather follicle and prevents feathers from growing back.

### Healthy Plumage




Photo: MAAARS

Feathers are smooth & glossy with an iridescent sheen in some species. Colors are rich and vibrant and feathers free of ragged edges, stress bars, or discolorations. Species such as a Cockatoos, African Greys, and Cockatiels emit a powdery down.

### Unhealthy Plumage




Photo: MAAARS

Generally dull and pale, and/or has ragged edges, black areas and stress marks.



The  
Avian Welfare  
Coalition  
[www.avianwelfare.org](http://www.avianwelfare.org)

This information herein is intended solely for use by animal shelter and care facilities to accommodate the short-term care and housing needs of captive birds in a shelter setting; not recommended for long-term care. The above guidelines are specific to birds kept as "pets" and surrendered to shelters. For medical care relating to wild birds, consult with a licensed wildlife rehabilitation organization. These materials are made possible through a generous grant from the ASPCA.®

# Common Physical Abnormalities of Captive Birds cont.

A bird that is feather plucking to the point of self-mutilation is a far more serious condition, and it can be life threatening.

Self-mutilating birds will chew through their own flesh, often in the breast area, and may extend to legs, wings, and toes. A chronically open wound on a bird can result in laceration, nerve and tissue damage, and/or infections.

Though feather plucking and/or mutilation are common among all captive bird species, these behaviors are seen more frequently in Cockatoos and African Grey parrots than in other species. In severe cases, birds will bleed to death from self-mutilation.

**Birds with bleeding or open wounds that are the result of feather mutilation should receive immediate medical care.**

## Self-Mutilating Cockatoo



## Plucked, but healthy



Blue & Gold Macaw



Conures



Congo African Grey



## OVERGROWN OR DEFORMED BEAKS

Beak overgrowth is often caused by a bird not having enough chewing aids to naturally trim their beak. Feeding a couple of almonds a day and offering branches or toys for chewing will help captive birds keep their beaks trimmed. If overgrowth interferes with their ability to eat, the bird's beak should be professionally trimmed.


Deformed beaks or severely overgrown beaks may be signs of other more serious medical conditions such as:

- Nutritional imbalances, malnutrition, lack of vitamin D
- Infections, mites
- Liver disease
- Trauma or injury
- Serious diseases (Psittacine Beak & Feather PBF)

An experienced avian veterinarian should determine the underlying cause of severe beak abnormalities.



Yellow-headed Amazon  
Overgrown beak due to neglect



African Grey  
Untreated sinus infection



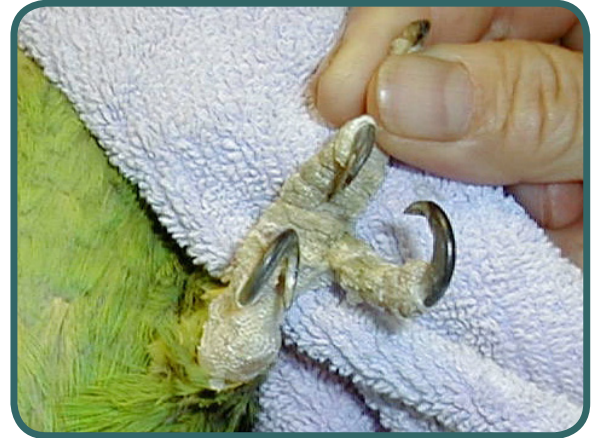# Common Physical Abnormalities of Captive Birds cont.



## OVERGROWN NAILS

Overgrown toenails make it difficult for a bird to properly perch, walk, or grasp their food. Severely curved or curled nails can be uncomfortable and endanger the bird by getting caught onto toys, cage bars, and fibers.

Nails should be short enough so that the bird can stand on a flat surface without the nail raising the toe off the surface. Providing natural branches for birds to rub their feet on can help keep their toenails trim. As a preventative measure, overgrown nails should be professionally trimmed.



Overgrown, curled nails



## MISSING TOES OR TOENAILS

Most birds have four toes; three pointing forward and one pointing backwards. Parrots, however, have four dexterous toes; two facing forward and two facing backward, which enables them to have a better grip on most objects.

Unless a bird's toe or foot is bleeding or they have a fresh wound upon arrival at the shelter, missing toes and toenails are generally the results of prior injury. Some birds experience a little difficulty gripping certain objects, but most of them function quite well despite their missing toes/toenails.

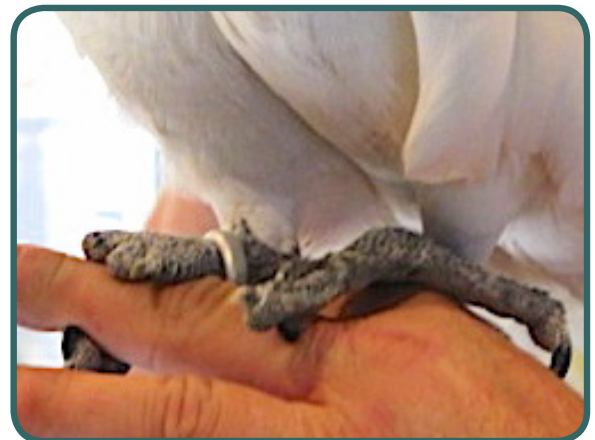A bird having difficulty perching or walking, appears to be in pain, or shows other signs of discomfort as a result of missing toes/toenails should be seen by a veterinarian.

Providing perches of differing diameters and textures that are appropriately sized for the bird helps to keep a bird's feet healthy.

Braided rope perches provide added comfort, but should be cleaned often to prevent build-up of droppings and debris. A corner triangular perch or platform with a flat surface helps to relieve pressure off a bird's feet, lessen any abrasions, and can aid their mobility.



Missing toes



Missing toenails

*Authored by Denise Kelly, President, The Avian Welfare Coalition  
Photos courtesy of: MAARS, Project Perry, and Foster Parrots*



The  
Avian Welfare  
Coalition  
[www.avianwelfare.org](http://www.avianwelfare.org)

This information herein is intended solely for use by animal shelter and care facilities to accommodate the short-term care and housing needs of captive birds in a shelter setting; not recommended for long-term care. The above guidelines are specific to birds kept as "pets" and surrendered to shelters. For medical care relating to wild birds, consult with a licensed wildlife rehabilitation organization. These materials are made possible through a generous grant from the ASPCA.®